

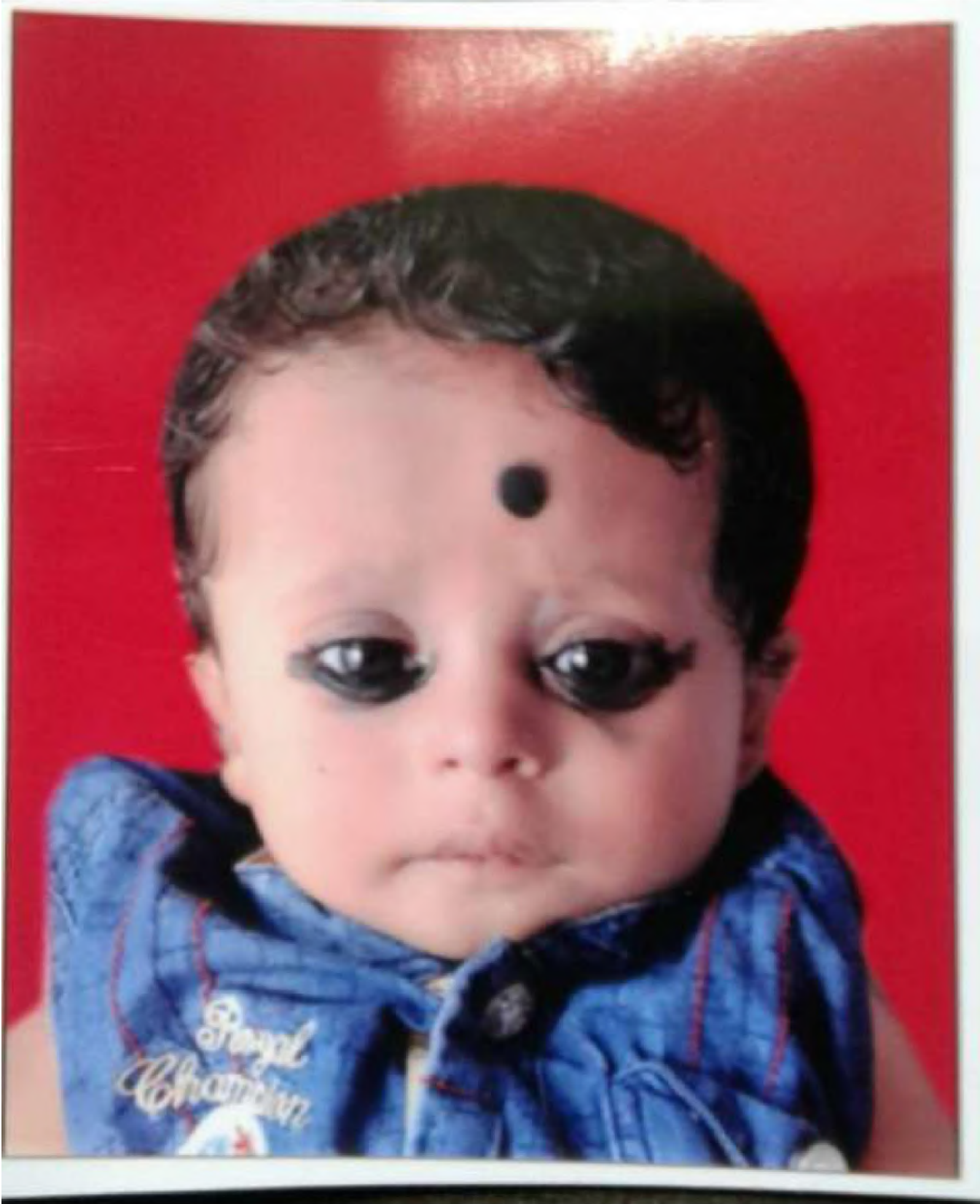

**Ocean Foundation Reg-353,  
Office address : D-127 3rd floor sector 10  
Noida gautam budha nagar (201301)  
Website : [www.oceanfoundations.org](http://www.oceanfoundations.org)  
Email : [info@oceanfoundations.org](mailto:info@oceanfoundations.org)**

## **PATIENT DETAILS FORM**

NAME	MASTER PRATIK KUMAR
FATHER NAME	AJAY KUMAR
CURRENT AGE	3 MONTHS
SEX	MALE
DISEASE NAME	VSD CLOSURE
HOSPITAL NAME	AIIMS NEW DELHI
ADDRESS	Baruraj, mujaffarpur , Bihar
FATHER OCCUPATION	labour
C.V NUMBER	2017/014/0018704
UHID NUMBER	102911980
TREATMENT REQUIRED	OHS (open heart surgery)
LAST VISIT IN HOSPITAL	19-06-2017
TREATMENT COST	57000/-
DEPARTMENT OF TREATMENT	CARDIOLOGY DEPTT. AIIMS NEW DELHI

Master Pratik is diagnosed as Heart Patient, Doctors accepted him for VSD closure. Estimated cost of operation is too high for Pratik's Family , as the do not have so much resources.Doctors asked to submit the amount ASAP so operation could be done in 2nd week of Aug 2017. Pratik's Father requested to **Ocean Foundation** for financial help.



CV 2017/014/0018704

Cardiology  
CTVS (89643/2017)

UHID: 102911980

Date 19/08/2017

MON, WED, FRI

Name PRATIK KUMAR

3M 5D /M

S/O AJAY KUMAR

Phone No. [Barcode]

Consultant Room 5

Dr. V. DEVAGOUROU

SR Room

[Barcode]

CHC-150617115 102911980  
[Barcode]

CHC-150617115 102911980  
[Barcode]

PRATIKKUMAR

दिनांक  
Date

UHID: 102911980

Paed. Cardiology

89543

विभाग  
Deptt.

Date 14/08/2017

FRI

Name PRATIK KUMAR

3M /M

S/O AJAY KUMAR

Phone No. [Barcode]

General

Consultant Room 18

Dr. S. RAMAKRISHNAN

SR Room 14

DR. SHAHEER

ब.रो.वि.सं.  
O.P.D. No.

[Barcode]

निदान  
Diagnosis

ACTH TRP

VD (L → R)

ML

Adv

Hb 10.7 gm%

Echc - large SAUSS (malaligned) & CVO.

plan - OHS.  
(explained)  
CXR awaited

① Symp Functed  
0.4ml QD

② Dixin Fed  
0.4ml QD

③ Symp Vitrofol 1/2 ml QD

15  
RSE, AV,  
BVH  
ML



दिनांक  
Date

R-18 (80)  
16/6/17

23/6/17

Refd in crs  
(85) W  
for USD closure

19.6.17

Accepted for USD closure ↓ Prof. V. Deygou.

R-18 (64)  
19/6/17

R-5  
19/6/17

- Deposit Rs 57000/- in MMMS CT PI Account
- Donate 400 blood in crs blood bank
- Bld grp of patient.

PDOA: 11/1/23

try for earlier  
date in ~~5~~ <sup>net</sup> 2 week  
2017

Long Waiting List & Consequences explained.  
In Case of Emergency to attend Casualty  
Advised to get Treatment from other Govt. Hospital

18  
N.W.W -

PRATIK KUMAR

# ECHOCARDIOGRAPHY REPORT

DEPARTMENT OF CARDIOLOGY, CARDIOTHORACIC CENTRE  
ALL INDIA INSTITUTE OF MEDICAL SCIENCES, NEW DELHI-110029

NAME Pratik Kumar AGE 3 Months SEX M DATE 14/6/2012  
 ECHO No. 17213 CV No. 18704 UHID No. 102911980 C.R. No. \_\_\_\_\_  
 HEIGHT \_\_\_\_\_ cm WEIGHT \_\_\_\_\_ kg BSA \_\_\_\_\_ m<sup>2</sup> Ref. Physician Dr. R.K.  
 Referring Diagnosis \_\_\_\_\_ Done by Dr. K. Prabhakar Checked by Dr. \_\_\_\_\_  
 Quality of Imaging Poor/Adequate/Good

## MITRAL VALVE

Morphology AML Normal/Thickening/Calcification/Flutter/Vegetation/Prolapse/SAM/Doming  
 PML Normal/Thickening/Calcification/Prolapse/Paradoxical motion/Fixed.  
 Subvalvular deformity Present/Absent Score \_\_\_\_\_  
 Doppler Normal/Abnormal  
 Mitral stenosis Present/Absent RR interval \_\_\_\_\_ msec  
 EDG \_\_\_\_\_ mmHg MDG \_\_\_\_\_ mmHg MVA \_\_\_\_\_ cm<sup>2</sup>  
 Mitral regurgitation Absent/Trivial/Mild/Moderate/Severe

## TRICUSPID VALVE

Morphology Normal/Atresia/Thickening/Calcification/Prolapse/Vegetation/Doming  
 Doppler Normal/Abnormal  
 Tricuspid stenosis Present/Absent RR interval \_\_\_\_\_ msec  
 EDG \_\_\_\_\_ mmHg MDG \_\_\_\_\_ mmHg  
 Tricuspid regurgitation Absent/Trivial/Mild/Moderate/Severe Fragmented Signals  
 Velocity \_\_\_\_\_ m/sec Pred. RSVP-RAP+ \_\_\_\_\_ mmHg

## PULMONARY VALVE

Morphology Normal/Atresia/Thickening/Doming/Vegetation  
 Doppler Normal/Abnormal  
 Pulmonary stenosis Present/Absent Level \_\_\_\_\_  
 PSG \_\_\_\_\_ mmHg Pulmonary annulus \_\_\_\_\_ mm  
 Pulmonary regurgitation Present/Absent  
 Early diastolic gradient \_\_\_\_\_ mmHg End diastolic gradient \_\_\_\_\_ mmHg

## AORTIC VALVE

Morphology Normal/Thickening/Calcification/Restricted Opening/Flutter/Vegetation No. of cusps 1/2/3/4  
 Doppler Normal/Abnormal  
 Aortic stenosis Present/Absent Level \_\_\_\_\_  
 PSG \_\_\_\_\_ mmHg Aortic annulus \_\_\_\_\_ mm  
 Aortic regurgitation Absent/Trivial/Mild/Moderate/Severe

midway  
2001/02 (52)

Site 10110. Area concerned.

- Large Sudd malachite pit type VSD. no PS.  
mild acid at cut site. Chemically not significant  
Can not be traced
- no additional VSD.
- area reasonably  
OK.

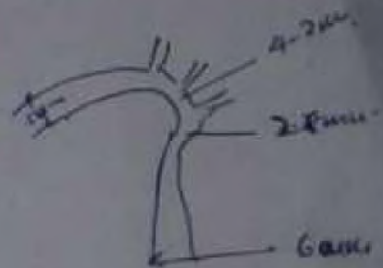
16/6/17



Measurements	Normal Values	LA es	Normal Values
Aorta	(21-22mm/m <sup>2</sup> )	13	(21-22 mm/m <sup>2</sup> )
LV es	(16-19mm/m <sup>2</sup> )	16	(19-32 mm/m <sup>2</sup> )
IVS ed	(16-10mm)	PW(LV)ed	(17-11mm)
RV ed	(4-14mm/m <sup>2</sup> )	RV Anterior wall	(upto 5mm)
EF	(62-80%)		
IVS Motion	Normal/Flat/Paradoxical		
IAS			

**CHAMBERS**

LV	Normal/Enlarged/Clear/Thrombus/Hypertrophy Contraction	Normal/Reduced
LA	Normal/Enlarged/Clear/Thrombus	
RA	Normal/Enlarged/Clear/Thrombus	
RV	Normal/Enlarged/Clear/Thrombus	



**PERICARDIUM**

Normal/Thickened/Calcification/Effusion

about  
Coronary

**REMARKS**

SS/LC | 2PV → LA | AAVA - C | ⊕ Aortic Aorta | NRCA

large 5/8 VSD, Aortic regurg ⊕, L/R duct

Additional Apical muscular VSD ⊕

**TEE**

no ASD, no PDA

transverse Aortic Hypoplasia, entire mid COA

gradual 29mm/kg

no duct

**DIAGNOSIS**

⊕ Bicuspid ⊕

**Final Impression**

ASD ⊕ | ↑ Qp | large 5/8 VSD | add apical muscular VSD |

transverse Aortic Hypoplasia | ⊕ Bicuspid ⊕

*[Signature]*  
Resident

Consultant

दिनांक  
Date

R-18 (80)  
16/6/17

23/6/17

Refd in crs  
(85) W  
for USD closure

19.6.17

Accepted for USD closure ↓ Prof. V. Deygou.

R-18 (64)  
19/6/17

R-5  
19/6/17

- Deposit Rs 57000/- in MMMS CT PI Account
- Donate 400 blood in crs blood bank
- Bld grp of patient.

PDOA: 11/1/23

try for earlier  
date in ~~5~~ <sup>net</sup> 2 week  
2017

Long Waiting List & Consequences explained.  
In Case of Emergency to attend Casualty  
Advised to get Treatment from other Govt. Hospital

18  
N.W.W -



आयकर विभाग  
INCOME TAX DEPARTMENT



भारत सरकार  
GOVT. OF INDIA



स्थायी लेखा संख्या कार्ड  
Permanent Account Number Card



**FNNPK2282R**

नाम/ Name  
AJIT KUMAR

पिता का नाम/ Father's Name  
LALDEV BHAGAT

जन्म की तारीख/ Date of Birth  
20/11/1992

*Ajit Kumar*

हस्ताक्षर/ Signature



07062017



भारत सरकार

GOVERNMENT OF INDIA



अजित कुमार

Ajit Kumar

जन्म तिथि/ DOB: 20/11/1992

पुरुष / MALE



8766 9393 8148

आधार-आम आदमी का अधिकार



भारतीय विशिष्ट पहचान प्राधिकरण  
UNIQUE IDENTIFICATION AUTHORITY OF INDIA

पता:

S/O: लालदेव भगत,  
बरुराज, बरुराज (मोतीपुर),  
मुजफ्फरपुर,  
बिहार - 843132

Address:

S/O: Laldev Bhagat, Baruraj, Baruraj  
(Motipur), Muzaffarpur,  
Bihar - 843132

8766 9393 8148

**Aadhaar**-Aam Admi ka Adhikar